

A Gene for Lymphedema-Distichiasis Maps to 16q24.3

J. Mangion,^{1,*} N. Rahman,^{1,*} S. Mansour,² G. Brice,³ J. Rosbotham,⁴ A. H. Child,³
V. A. Murday,² P. S. Mortimer,⁴ R. Barfoot,¹ A. Sigurdsson,¹ S. Edkins,¹ M. Sarfarazi,⁷
K. Burnand,⁵ A. L. Evans,³ T. O. Nunan,⁶ M. R. Stratton,¹ and S. Jeffery²

¹Institute of Cancer Research, ²Medical Genetics Unit and Departments of ³Cardiological Sciences and ⁴Dermatology, St. George's Medical School, Departments of ⁵Academic Surgery and ⁶Nuclear Medicine, United Medical and Dental School, St. Thomas' Hospital, London; and ⁷Surgical Research Center, Department of Surgery, University of Connecticut Health Center, Farmington

Summary

Lymphedema-distichiasis (LD) is a dominantly inherited syndrome with onset of lymphedema at or just after puberty. Most affected individuals have distichiasis—fine hairs arising inappropriately from the eyelid meibomian glands—which is evident from birth. A study of three families with LD has shown linkage to chromosome 16q24.3, and subsequent analysis of the region for recombinant genes places the locus between D16S422 and D16S3074, a distance of ~16 cM. Possible candidate genes in this interval include the N-proteinase for type 3 collagen, PCOLN3; the metalloprotease PRSM1; and the cell matrix–adhesion regulator, CMAR.

Introduction

Primary lymphedema (MIM 153200) is edema that occurs as a consequence of a failure of lymph drainage and arises from an intrinsic abnormality of the lymphatic system (Mortimer 1995). The lymph-conducting pathways are assumed to be congenitally abnormal, although lymphedema may not manifest until later in life. Thirty-five percent of all patients with primary lymphedema have a positive family history (Dale 1985). Primary lymphedema can be present at birth, as in Milroy disease, but it more commonly has a later onset, developing at or after puberty, when it is termed “Meige disease” (Goodman 1962; Wheeler et al. 1981; Herbert and Bowen 1983). Meige disease represents 80% of lym-

phedema cases and is thought to be due to gradual obliteration of the peripheral lymphatic system.

A gene for Milroy disease has recently been located on chromosome 5 by members of our consortium and others (Ferrell et al. 1998; Evans et al. 1999 [in press]). The loci responsible for Meige disease have been more elusive (Hardy et al. 1995). Genetic heterogeneity between families and establishment of phenotype are the most likely causes of this failure to locate the loci. We have therefore chosen to study a specific form of lymphedema: lymphedema-distichiasis (LD) (MIM 153400). This syndrome, a rare cause of primary lymphedema (Robinow et al. 1970; Dale 1987), is associated with congenital distichiasis (fine hairs arising inappropriately from the openings of the meibomian glands on the inner eyelid), which may cause severe irritation of the cornea. LD is inherited as an autosomal dominant disorder with variable expressivity and penetrance (Temple and Collin 1994). Associated features of LD have been reviewed by Temple and Collin (1994) and include congenital heart defects, vertebral anomalies, extradural cysts, ptosis (Kinmonth et al. 1957), and cleft palate.

Subjects and Methods

Three families with LD were identified by the genetics and surgical departments of St. George's and St. Thomas' Hospitals, London. All studies were performed with the full informed consent of the patients, and ethical permission was obtained from the local ethics committees at St. George's and St. Thomas' Hospitals. Individuals within these families were subject to clinical examination whenever this was practical. Family 3 was further investigated by use of lymphoscintigraphy in clinically affected and unaffected family members (J. Rosbotham et al., unpublished data). Lymphoscintigraphy is based on the principle that the essential function of the lymphatic system is to return to the vascular compartment those proteins and colloids that are too large to reenter directly. The dynamics of lymph flow—as depicted by the uptake of technetium-99m rhenium sulfur colloid, its transit via the lymphatic vessels, and its trap-

Received February 8, 1999; accepted for publication June 8, 1999; electronically published July 15, 1999.

Address for correspondence and reprints: Dr. S. Jeffery, Medical Genetics Unit, St. George's Medical School, Cranmer Terrace, Tooting, London SW17 0RE. E-mail: sggt100@sghms.ac.uk

*These two authors contributed equally to this work.

© 1999 by The American Society of Human Genetics. All rights reserved.
0002-9297/99/6502-0018\$02.00

Table 1**Clinical Details for the Members of Families 1 and 2**

Family and Individual	Lymphedema	Distichiasis	Venous Insufficiency ^a	Congenital Anomaly
Family 1:				
1.I.1	Present (history)	Recurrent conjunctivitis	Varicose veins	
1.II.2	Present	Present	Varicose eczema	
1.II.3	Mild postural (history)	Normal (history) (not examined)	Absent	
1.II.4	Present	Present	Atrophic hyperpigmented skin	
1.II.5	Present	Present	Varicose veins, ovarian varicoceles	Ventricular septal defect, mitral and aortic regurgitation, sinus bradycardia
1.III.1	Absent	Present	Absent	Synophrys
1.III.2	Present	Present	Varicose veins	Sinus bradycardia
1.III.3	Not examined	Not examined	Varicose veins	Cleft palate
Family 2:				
2.I.2	Present (history)	Not examined	Not examined	
2.II.1	Present	Present	Varicose veins, eczema	
2.II.3	Present (history)	Present (history)	Not examined	
2.III.1	Normal	Normal	Normal	
2.III.3	Present (history)	Present (history)	Not examined	Ptosis
2.III.5	Present	Present	Normal	Synophrys, kyphosis
2.IV.1	Mild swelling	Present	Varicose veins	Ptosis
2.IV.2	Normal	Present	Absent	
2.IV.3	Present	Present	Normal	Synophrys, Fallot tetralogy

^a Determined by clinical examination.

ping in regional lymph nodes—are studied by use of either a scintiscanner or a gamma camera with a large field of view (Stewart et al. 1985).

Because distichiasis is rare, all family members with definite distichiasis were classified as affected, with or without lymphedema. In the absence of distichiasis, a family member was considered to be affected if he or she had either severe early-onset lymphedema or a positive result on lymphoscintigraphy plus one of the aforementioned associated anomalies. Venous insufficiency is so common in the general population that it was not used as a criterion for diagnosis; however, it was noted to be present in a high proportion of affected individuals (J. Rosbotham et al., unpublished data), often with a premature onset. For example, in family 2, individual 2.IV.1 had varicose veins beginning at 12 years of age and had an operation to strip the saphenous vein at 16 years of age.

In families 1 and 2, there were two individuals in whom distichiasis occurred without lymphedema. Individual 2.IV.2 in family 2 was prepubertal (13 years of age) at the time of this study, but individual 1.III.1 was 19 years of age and showed no sign of limb edema. Individual 3.III.3 in family 3 could not be examined for distichiasis, but he was considered to be positive for the condition according to the other criteria previously mentioned. He had very severe lymphedema with onset early

in childhood and, in addition, had ptosis, which was inherited from his father. Ptosis, which has been previously associated with LD, was identified in three affected individuals in this study and was reported in another individual in another study (Kinmonth et al. 1957).

On the basis of our classification, there were three individuals in family 3 who were difficult to assign: 3.II.8, 3.II.11, and 3.III.5 (fig. 1). Individual 3.II.8 is an 80-year-old man who has mild swelling of the dorsum of the left foot and abnormal findings on lymphoscintigraphy on the same side. However, he denied having had lymphedema when younger, had no other associated anomalies, and, despite his age, had no venous insufficiency either clinically or on testing with light-reflective rheography. Although his age and cardiac failure, for which he was taking digoxin, are likely to explain the observed abnormalities, we have classified him as being of unknown status. Individual 3.II.11 had no clinical manifestations of LD, but she claimed to have had leg swelling as an adolescent and has, at 30 min, a unilateral abnormal lymphoscintigraphy result that, by 60 min, is within normal limits. There is some uncertainty with regard to the interpretation of lymphoscintigraphy results on early readings. Protocols vary and some centers ignore the results at 30 min, placing more emphasis on later readings (Proby et al. 1990). Mild pitting edema was evident on examination of individual 3.II.11, but

Table 2**Clinical Details for the Members of Family 3**

Family 3	Lymphedema	Distichiasis	Venous Insufficiency ^a	Lymphosyntigraphy	Congenital Anomaly
3.II.1	Normal	Normal	Normal	Normal	
3.II.2	Present (history)	Not examined	Not examined	Not performed	
3.II.4	Present (history)	Not examined	Not examined	Not performed	Ptosis
3.II.6	Present (history)	Not examined	Not examined	Not performed	
3.II.8	Mild swelling (no history)	Normal	Normal	Positive (in heart failure)	
3.II.10	Present	Present	Uncertain	Positive	
3.II.11	Normal	Normal	Present	Positive, normal at 60 min	
3.III.1	Normal	Normal	Present	Normal	
3.III.2	Normal	Normal	Normal	Normal	
3.III.3	Present	Normal	Uncertain	Positive	Ptosis
3.III.5	Normal	Normal	Normal	Normal at 60 min	
3.III.6	Normal	Normal	Present	Normal	
3.III.7	Present	Present	Uncertain	Positive	
3.III.9	Present	Present	Present	Positive	
3.III.10	Normal	Normal	Normal	Normal	
3.III.11	Present	Present	Present	Positive	
3.IV.1	Normal	Normal	Normal	Normal	
3.IV.2	Normal	Normal	Normal	Normal	
3.IV.3	Present	Present	Present	Positive	Congenital heart disease
3.IV.4	Normal	Present	Present	Normal	
3.IV.5	Normal	Not examined	Present	Normal	

^a Determined by light-reflective rheography. "Uncertain" indicates that the readings were equivocal.

findings on lymphoscintigraphy were not as abnormal as would be expected for an individual said to have such long-standing disease. She does not fulfill the criteria for affected status, but, in view of the uncertainty, we have included her as being of unknown status. Individual 3.III.5 has no lymphedema on examination, but has, at 30 min, an abnormal lymphoscintigraphy result and a normal result at 60 min. He has no other associated features. In view of his lymphoscintigraphy result, we have been cautious and have included him as being of unknown status.

Some family members could not be assigned definite status because a full clinical examination was not conducted. In family 1, this was the case for individuals 1.II.3 and 1.III.3. In the former subject, an examination was not possible, but details obtained from a telephone conversation suggested that she was unaffected. Individual 1.III.3 had a cleft palate, and other family members were convinced that he was affected; however, the patient refused to be examined. Neither patient was used in the linkage analysis.

DNA was extracted from peripheral-venous-blood samples by conventional methods. Polymorphic micro-satellite markers, predominantly from the Généthon set, were PCR amplified and electrophoresed through 4.5% denaturing polyacrylamide gels either on an ABI377 DNA sequencer or on a conventional gel rig. For PCR products electrophoresed on the ABI377, one oligonucleotide primer was end-labeled during synthesis with a

fluorescent tag, and the results were analyzed by use of GENESCAN and GENOTYPER software. For conventional PAGE, one PCR primer was end-labeled by T4 polynucleotide kinase and [³²P]-ATP, and the gel was exposed to autoradiography film for 1–16 hr.

The two-point and multipoint analyses were performed by the MLINK suite of programs. The model used was one in which disease alleles were given a frequency of .0001, penetrance was set at 90%, and no sporadic cases were allowed.

Results

Results of the clinical examinations are shown in tables 1 and 2, and pedigrees of the three families, including haplotypes D16S511–D16S3074, are illustrated in figure 1. The clinical data are provided in two tables because only family 3 had lymphoscintigraphy.

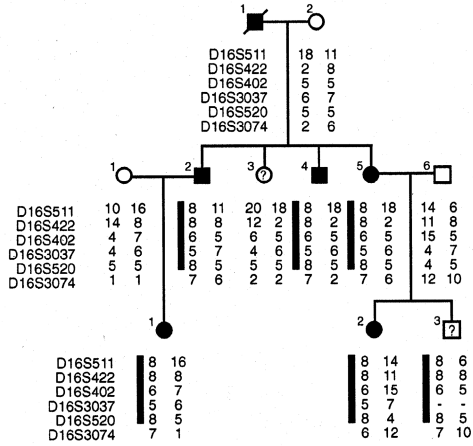
The framework-genomewide search, which used 220 markers, yielded three areas—on chromosomes 2, 10, and 16—with a total LOD score >1 obtained for the three families. Analysis of further markers in the first two regions showed that there was no cosegregation of the same haplotype with the disease. Marker D16S514 gave an initial two-point LOD score of 5.4 at recombination fragment (θ) 0 (table 3), and, on typing additional markers, the maximum two-point LOD score obtained in this region was 5.86 for D16S3037. Three-point analysis for D16S3037 and D16S520 gave

A.

I

II

III



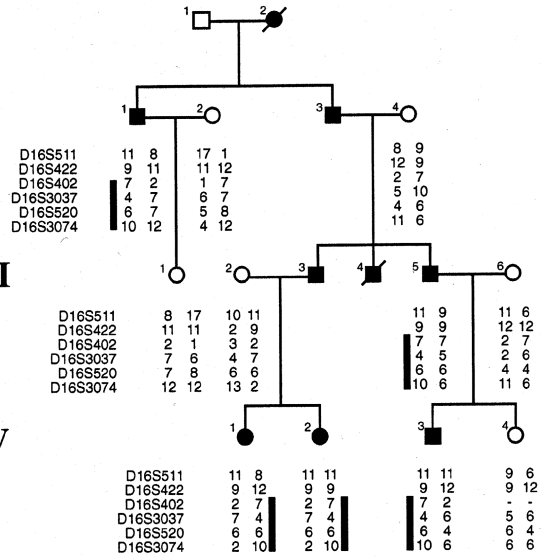
B.

I

II

III

IV



C.

I

II

III

IV

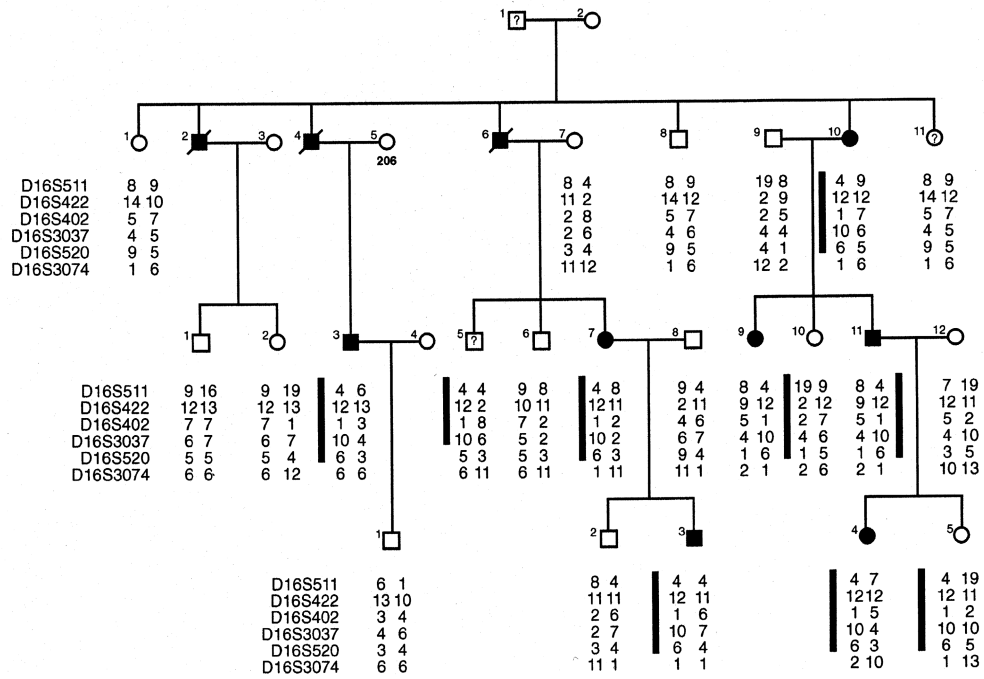


Figure 1 Family 1 (A), family 2 (B), and family 3 (C), with haplotypes for the markers shown. Markers are shown in the order, on the chromosome, predicted by use of the Généthon map.

Table 3
Two-Point LOD Scores for the Markers Shown on the Pedigrees

MARKER	LOD SCORE AT $\theta =^a$								
	0	.05	.1	.15	.2	.25	.3	.35	.4
D16S511	1.47	4.76	4.51	4.09	3.57	2.98	2.34	1.67	1.01
D16S422	-.87	2.6	2.53	2.3	1.99	1.62	1.23	.84	.48
D16S402	4.61	4.32	3.94	3.5	3.01	2.48	1.93	1.36	.8
D16S3037	5.86	5.43	4.92	4.37	3.77	3.13	2.47	1.77	1.08
D16S520	5.4	4.98	4.48	3.95	3.37	2.76	2.13	1.5	.87
D16S3074	-10.11	.59	1.16	1.32	1.29	1.15	.93	.68	.41

^a LOD scores are for all three families combined.

a LOD score of 6.19 at $\theta = 0$ (table 4). Recombination events for D16S3074 and D16S422 place these markers at the limits of the mapped area for the gene, which is a distance of ~16 cM according to the Génethon LOD 3 map. Overall, all three families have findings that are consistent with linkage to a locus on chromosome 16q.

Discussion

The difficulties encountered in linkage analysis of primary lymphedema (Hardy et al. 1995) led us, in this study, to use LD in which the distichiasis provided a clear phenotype by which to define affected status. The establishment of linkage to chromosome 16q24.3 has justified this approach, and analysis of linked markers in a wider set of families with primary lymphedema is now indicated. The two clinical signs in this condition show quite different ages at onset; distichiasis is present from birth, whereas the onset of lymphedema occurs in puberty or later. Distichiasis is not the presence of a second row of eyelashes from the tarsal plate but, rather, is the development of hairs from the meibomian gland, an organelle that normally has a sebaceous function. This strongly suggests that the gene(s) responsible for this condition is (are) concerned with development. It is possible that there is more than one gene involved, since there are families in which either distichiasis or lymphedema occurs in isolation (Temple and Collins 1994); however, the condition may be due to a single gene with variable expression and penetrance. At the density of markers used in the present study, there are no obvious similarities seen between the segregating haplotypes in the three families.

There are no affected individuals in the three families that carry a haplotype inconsistent with linkage. However, in family 3, there is one affected individual (3.IV.5) who carries the full affected haplotype. She does not fulfill any of the inclusion criteria, although she does show marked venous insufficiency at the age of only 26 years. According to our criteria, this would be classified as nonpenetrance, but, if future clinical studies show that

venous insufficiency is associated with LD, then it would be considered to be reduced expression. In the same family, there is one unassigned individual (3.III.5) who has part of the haplotype and is of uncertain status, as described in the Subjects and Methods section. He carries the top four markers of the affected haplotype and shares the lowest two with his unaffected brother (3.III.6). Even though the lymphoscintigraphy results for individual 3.III.5 are normal at 60 min, it is not possible to use this finding to define his status, since a very similar picture is seen for individual 3.IV.4, who is known to be affected because she has distichiasis. Thus, we know that the case of individual 3.III.5 refines the interval, but it is impossible to say in which direction.

The pubertal onset of lymphedema is suggestive of a hormonal effect acting on a pre-existing structural malformation in the lymphatic vessels, which would explain why there is a difference in the onsets of distichiasis and lymphedema. It is of interest that follicular tumors may show sebaceous differentiation (Lever 1997). There would therefore seem to be a dual developmental pathway for these glands, and the gene involved in LD may well be involved with the determination of the correct path. Although there are no strong candidate genes in the interval, the N-proteinase for type 3 collagen and the cell matrix-adhesion regulator are possible contenders. It is conceivable that either of these proteins could

Table 4
Multipoint LOD Scores

Family	LOD Score at $\theta =^a$								
	0	.05	.1	.15	.2	.25	.3	.35	.4
1	1.16	1.05	.94	.82	.7	.57	.44	.32	.2
2	3.19	3.03	2.8	2.53	2.21	1.85	1.46	1.04	.6
3	1.84	1.66	1.47	1.28	1.08	.89	.69	.51	.33
Total	6.19	5.74	5.21	4.63	3.99	3.31	2.59	1.87	1.13

^a LOD scores are for individual families and for all three families combined. An unknown status is assumed for individual 3.III.5 in family 3 (see Discussion section).

play a role in lymphatic structure and, perhaps, in development as well.

Acknowledgments

We would like to thank the Birth Defects Foundation. A.H.C., A.L.E., G.B., and J.R. are grateful to the Bluff Field Charitable Trust, the Marfan Trust, and the St. George's Hospital Special Trustees for their generous support. We are also grateful to Dr. Hindola Konrad, at Moorfields Eye Hospital, for helping us with ophthalmological examinations.

Electronic-Database Information

Accession numbers and URLs for data in this article are as follows:

Généthon, <ftp://ftp.genethon.fr/pub/Gmap/Nature-1995/data>
Online Mendelian Inheritance in Man (OMIM), <http://www.ncbi.nlm.nih.gov/Omim> (for lymphedema [MIM 153200] and LD [MIM 153400])

References

- Dale RF (1985) The inheritance of primary lymphoedema. *J Med Genet* 22:274-278
- (1987) Primary lymphoedema when found with distichiasis is of the type defined as bilateral hyperplasia by lymphography. *J Med Genet* 24:170-171
- Evans AL, Brice G, Sotirova V, Mortimer P, Rosbotham J, Beninson J, Burnand K, et al (1999) Mapping of primary congenital lymphedema to the 5q35.3 region. *Am J Hum Genet* 64:547-555
- Ferrell RE, Levinson KL, Esman JH, Kimak MA, Lawrence EC, Barmada MM, Finegold DN (1998) Hereditary lymphedema: evidence for linkage and genetic heterogeneity. *Hum Mol Genet* 7:2073-2078
- Goodman RM (1962) Familial lymphedema of the Meige's type. *Am J Med* 32:651-656
- Hardy C, Child A, Jeffery S, Weber J, Farndon P (1995) Linkage analysis in primary lymphoedema. Abstract presented at the meeting of the British Society of Clinical Genetics, York, England, September 11-13
- Herbert FA, Bowen PA (1983) Hereditary late-onset lymphedema with pleural effusion and laryngeal edema. *Arch Intern Med* 143:913-915
- Kinmonth JB, Bryant JS, Gruber D, Townes PL (1957) Primary lymphoedema: clinical and lymphangiographic studies of a series of 107 patients in which the lower limbs were affected. *Br J Surg* 45:1-11
- Lever W (1997) Tumours of the epidermal appendages. In: Elder D, Elenitsas R, Jaworsky C, Johnson JR (eds) *Lever's histopathology of the skin*, 8th ed. Lippincott-Raven, Philadelphia, pp 747-803
- Mortimer PS (1995) Managing lymphoedema. *Clin Exp Dermatol* 20:98-106
- Proby CM, Gane JN, Joseph AE, Mortimer PS (1990) Investigation of the swollen limb by isotope lymphography. *Br J Dermatol* 123:29-37
- Robinow M, Johnson GF, Verhagen AD (1970) Distichiasis-lymphedema: a hereditary syndrome of multiple congenital defects. *Am J Dis Child* 119:343-347
- Stewart G, Gaunt JI, Croft DN, Browse NL (1985) Isotope lymphography: a new method of investigating the role of the lymphatics in chronic limb oedema. *Br J Surg* 72:906-909
- Temple IK, Collin JR (1994) Distichiasis-lymphoedema syndrome: a family report. *Clin Dysmorphol* 3:139-142
- Wheeler ES, Chan V, Wassman R, Rimoin DL, Lesavoy MA (1981) Familial lymphedema praecox: Meige's disease. *Plast Reconstr Surg* 67:362-364